Food and Foreign Body Impaction in Upper GI Tract

M. Yasser Abu-Safieh MD

Specialized Arab Hospital

Nablus - Palestine

Abstract

- **<u>Background</u>**: Ingestion of foreign bodies and food impaction are the most common cause of esophageal obstruction, which is considered as acute emergency, this obstruction can be caused by soft, blunt, and sharp objects. Endoscopy is considered as the main therapeutic procedure, surgical intervention is rarely needed.

- **Methods**: A retrospective study of all patients' records with acute esophageal obstruction or presence of radio-opaque foreign body in esophagus or stomach. Urgent EGD used to be done in outpatient clinic, or elective, if the patient has the foreign body days in the stomach. XQ10, XV10, and Q20 Olympus gastroscopes were used, retrieval was carried out by snare or tetrapode grasper, over tube was used once indicated. Conscious sedation, by using titrated doses of Midazolam, or GA, if sedation was not enough. Patients were classified according to esophageal pathology, and type of obstructing object.

- **Results:** All records of 77patients from 1992-Nov 2003 presented with either esophageal obstruction, or a radio-opaque shadow were reviewed, mean age 28.2 years (1-80 years), total events 81, M:F 38:39, total number of EGD in that period 4522. Cause of obstruction, and management were as follows:-

Type of Foreign body	Retrieved	Pushed	Stricture	Referred to surgery
Meat (30) * Plant (5)	28 4	2 1	28 3	
Coins (17) ** Coin like (7)	11	13 pushed & removed		
Bones (7) *** Dental Bridge(4)	3 1	2 3		2 perforated
Total (70)	(47)	(21)	(31)	(2)

* Soft, ** Blunt, ***Sharp

Four patients with gastric bezoars, 3 were removed, and one trichobezoars was fragmented and pushed completely on 3rd session. Three pins, in 3 patientswere embedded in full stomach and could not be seen, passed with stool. The blade was removed by snare with over tube protection. And in 3 patients negative EGD.

- **Conclusion:** foreign bodies and impacted food can be successfully managed by gastroscopy in most cases, (93%). Failure is due to embedded bones in upper esophagus, and surgery is the treatment. Either extracting or pushing techniques are effective. Coins and coins like impaction occurred in normal esophagus, mainly in children, while soft bolus impaction occurred in an abnormally narrowed esophagus.

Introduction

- **A**cute esophageal obstruction is a common problem in clinical practice.[1]
- Usually the patient will present at the time of food or foreign body impaction, distressed, sometimes dehydrated if the esophagus is totally obstructed, and retrosternal pain.[1,2]
- Only 10-20% of patients need help, and go to emergency room.[1-5]

- Physicians of different specialty tried their best to help such patients, by inserting esophageal dilators, or a Foley's catheter blindly or using fluoroscopy, sometimes they may succeed.[5-9] Contrast radiography to localize the food bolus, will add difficulties to endoscopic procedures [5, 10, 11].
- Rigid and flexible endoscopes are used in managing patients with esophageal impaction, flexible endoscopes are less expensive, need not to have general anesthesia, i.e., conscious sedation will be enough in most cases. Success rate is above 90% in most of the recent retrospective studies using flexible endoscopes. [1,2,6, 9,12]

Materials and methods:

- A retrospective study of medical records and video tapes, of patient who presented with either, food or foreign body impacted in the esophagus, or the radio-opaque shadow is still seen in the gastric cavity after days of ingestion.
- Seventy seven patients were included, from Jan 1992—Nov 2003; all patients were referred for endoscopy. XQ10, XV10 and Q20, Olympus gastroscope were used, different types of snares, tetrapode graspers to pull or push the impacted object.
- Over tube was used if a sharp foreign body was ingested. Conscious sedation by using Midazolam, (Roche) or Propofol if can not sedate the patient especially in children.

- General anesthesia if conscious sedation was not enough. The aim is to relieve obstruction by retrieving the impacted object, or pushing it into the stomach and then retrieving it, if not food. The patient was referred to surgery if perforation of esophagus was suspected during the procedure.
- Dilatation of esophagus by using Savary-Gilliard dilators (Wilson-Cook Medical, Inc., Winston –Salem, N.C.)
- One patient with large trichobezoars in the stomach extending to the duodenum, and after failure of several trials of removing or crushing it, concentrated nitric acid was used to soften it and make it easier to deal with.

The impacted objects were classified into soft, blunt and sharp Patients' age, sex, and history of previous esophageal symptoms were recorded. Children were identified as less than 15 years old.

Results:

- The total number of upper endoscopies was 4522 in that period (Jan92-Nov2003) total number of patients with food and foreign body impacted in esophagus or radio-opaque shadow in the stomach was 77patients, mean age 28.2 years (1-80) year.
- Total episodes were 81 for 77 patients,39 female, 38 male, 35children, 42 adult.
- Conscious sedation by Midazolam used in the majority (94%), except in 5 patients, (2 sedated by Propofol and 3 patients by general anesthesia and endotracheal intubations).

Impacted objects were as follows:-

Table (1): Soft objects, total 35 patients.

Type of objects	**Meat** **Plant and seeds**	**30** **5 (garlic 2 , orange 2, loquat 1)**
Type of stricture	**Corrosive** **GERD** **Schatzki's ring** **No Stricture**	**15 (11 children, 4 Adults)** **10 (Adults)** **6 (Adults)** **4 (Adults)**
Age Group	**Adults** **Children**	**24** **11**
Management	**Retrieved** **Pushed**	**32** **3**

Dr1

Figure 1: Different types of soft objects, upper 2 boluses of meat, lower, a lobe of garlic.

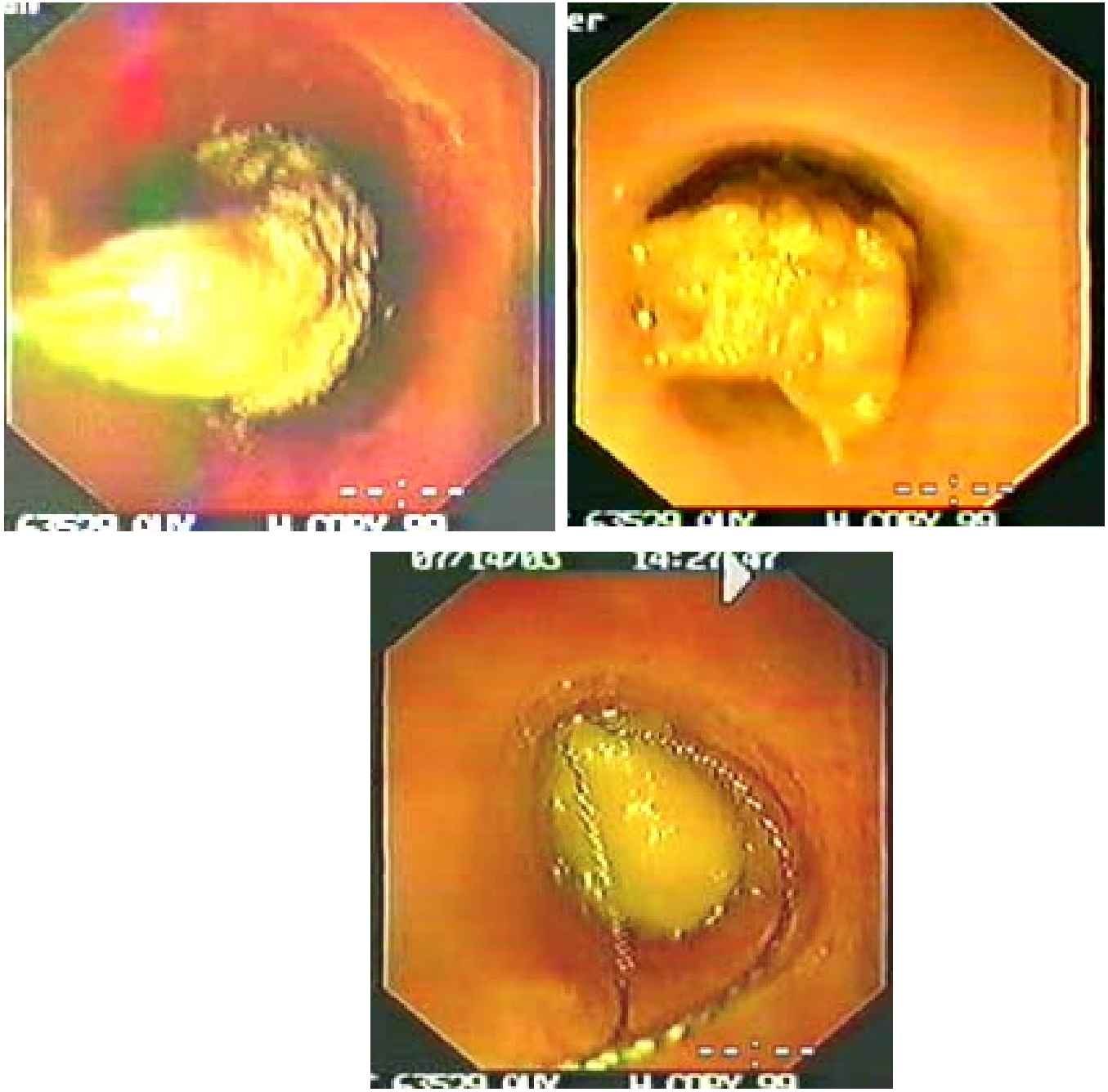

Slide 14

Dr1 Figure 1: Different types of soft ojects, upper 2 boluses of meat, lower,a lobe of garlic

yasser; 14/04/2004

Table 2: Blunt objects, 24 patients, all were children (mean age 5.4 years)

Type	Number
Coins	(17)
Coins like (7)	(3) Disc batteries (2) Buttons (1) Plastic ring (1) Marble
Management	(11) Retrieved (13)Pushed and retrieved from stomach

Table (2): Blunt objects, total 24 patients Coins (17) Coins like (7)

Figure 2: Blunt objects, upper: 2 different coins, lower: plastic ring

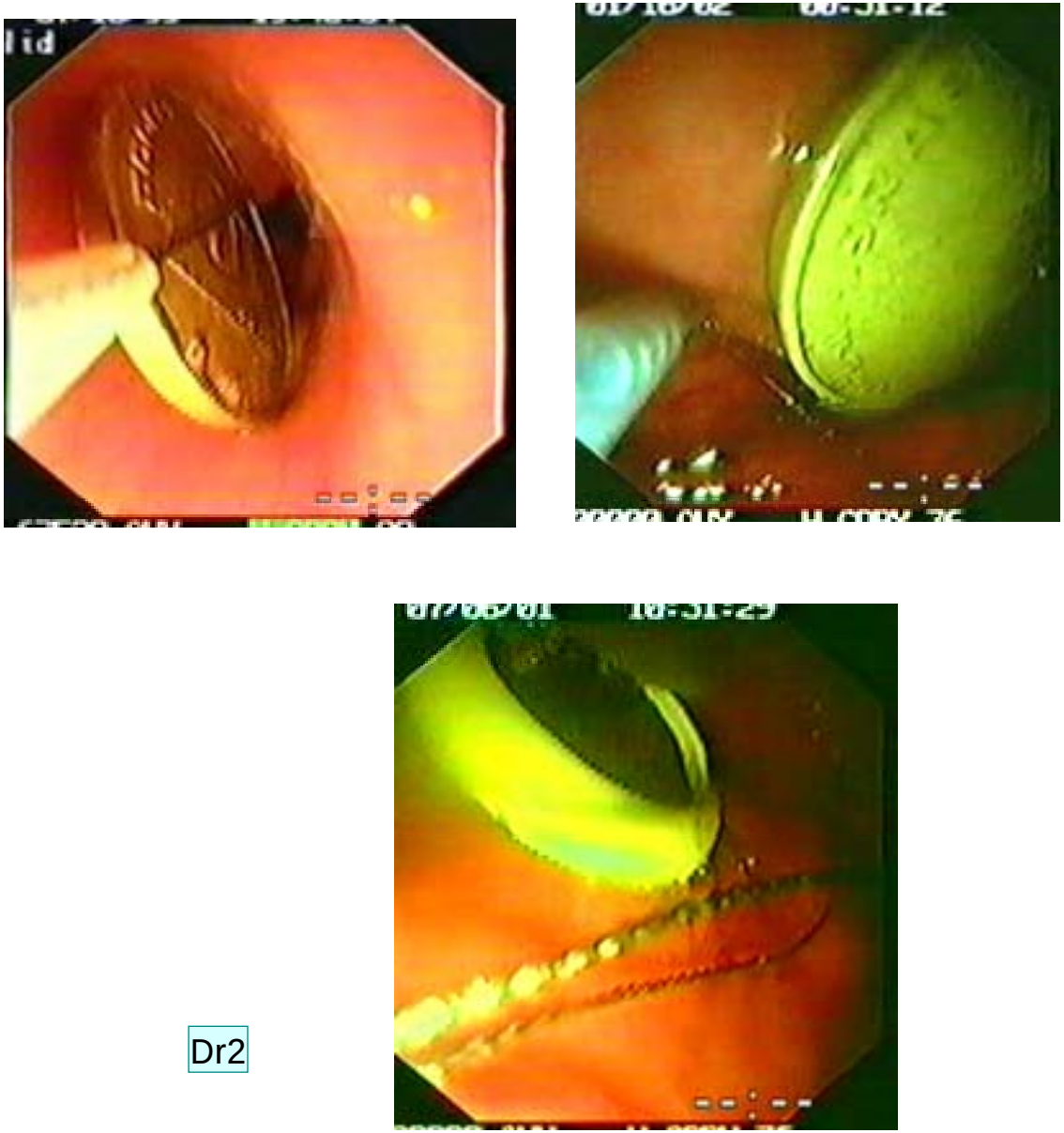

Dr2

Dr2 Figure 2: Blunt obects, upper 2 different coins, lower plastic ring

yasser; 14/04/2004

Table 3: Sharp Objects, 15 patients

Type	Number	Pushed	Retrieved	Comment
Bone	(7)	(2)	(3)	(2) perforated & operated upon
Dental bridge	(4)	(3)	(1)	(1) impacted in rectum, removed manually
Pins	(3)			(3) mixed with food, defecated
Razor blade	(1)		(1)	3 pieces retrieved using over tube

Figure 3: Sharp objects, upper 2 embedded pieces of bone, lower razor blade, & dental bridge.

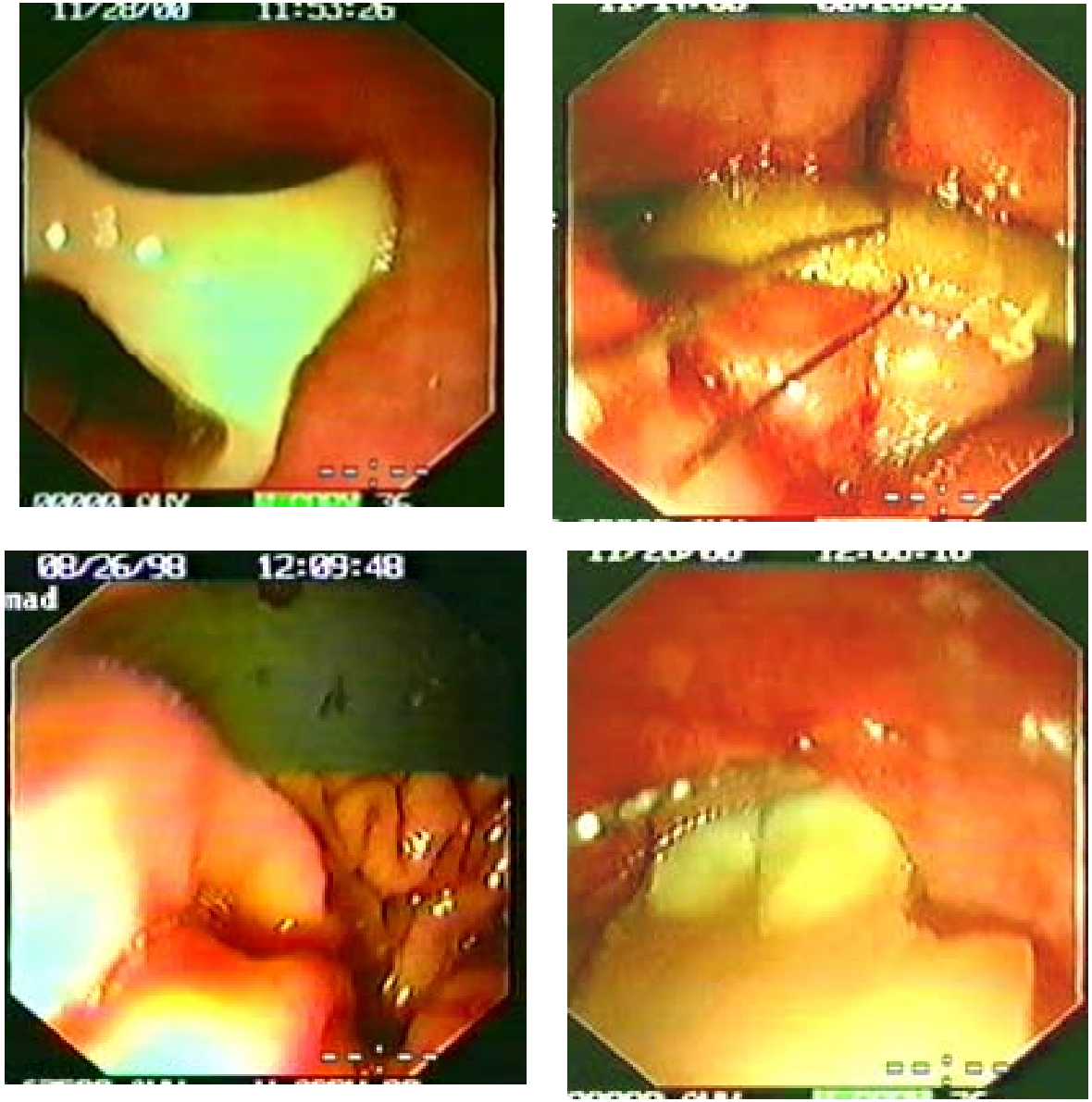

Dr3

Slide 18

Dr3 Figure 3: Sharp objects, upper 2 peices of bone, embeded in esopagus, lower razor blade, dental bridge.
yasser; 14/04/2004

Table 4: Gastric bezoars, 4 patients

Type	Number	Management
Phytobezoars	(3)	**Fragmented & removed by snare**
Trichobezoars (in a 14 year old girl)	(1)	**Injected with concentrated nitric acid, softened, came out with stool (large extending from antrum to duodenum, causing jaundice and cachexia)**

Figure 4: Tricobezoars, injected by nitric acid

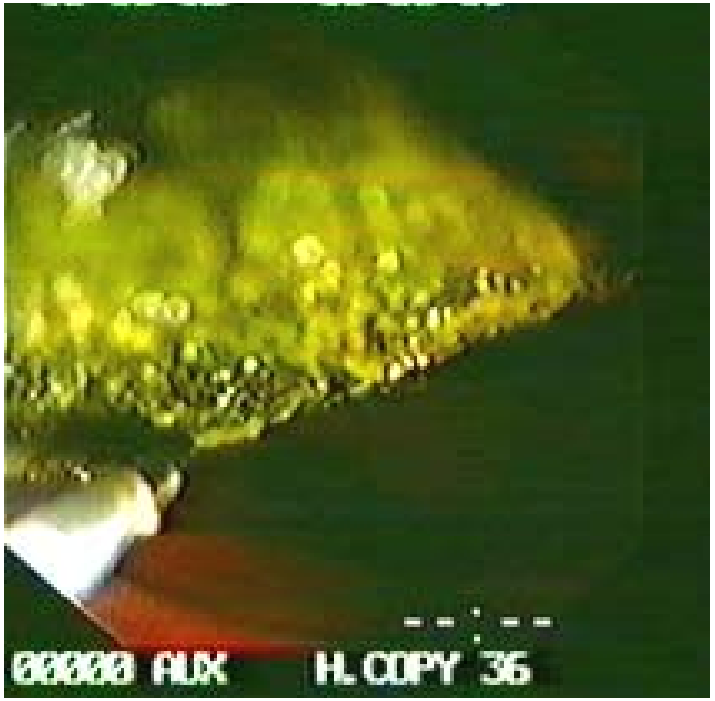

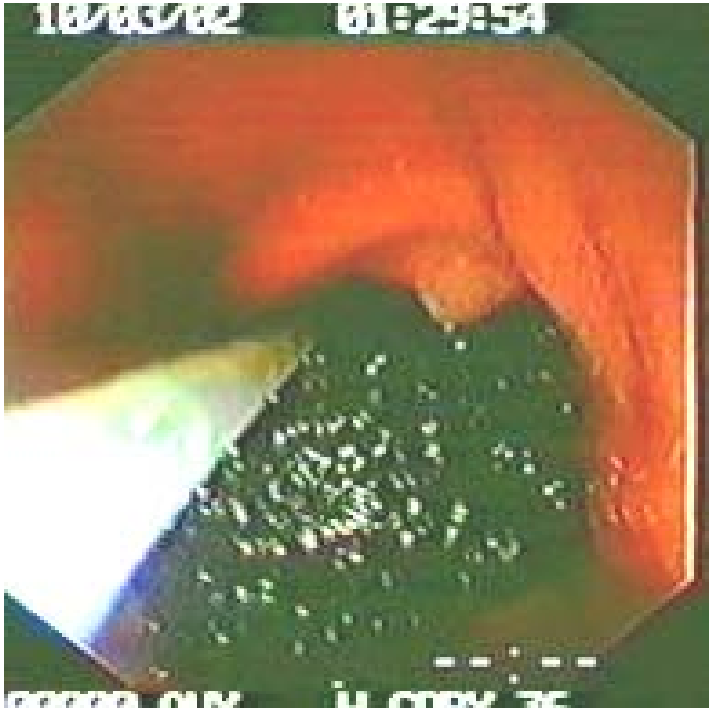

Dr4

Slide 20

Dr4 Figure 4: Tricobezoars, injected by nitric acid

yasser; 14/04/2004

Underlying esophageal lesions:

- After removing or pushing the obstructing object, the esophagus was examined for underlying pathology and esophageal stricture was found in 31 patients and all have soft food boluses, the cause of stricture was acid stricture (GERD) in 10 patients while 15 with history of corrosive stricture (11 children, 4 adults) and 6 with Schatzki's ring. No patient with blunt or sharp object has stricture.
- Dilatation used to be done for all patients with esophageal stricture, either before discharge, or 1-2 weeks later if the food bolus impacted in the esophagus more than 24 hours. None of the patient with blunt or sharp foreign bodies had underlying pathology in the esophagus

Negative EGD:

- Three patients had negative endoscopy, tow patients, the coins were not found in the stomach or duodenum as the X-ray film showed, and one obsessive patient who thought a piece of bone was still in his esophagus.

Discussion

- ASGE guidelines, and the review of literature, foreign bodies and food impacted in esophagus are important and may threaten the life of patients.[5] Minority of patients, less than 20%, present to physicians, while the majority will pass such foreign bodies without complication.[1-4,9,11,13]
- For the last 30 years flexible but not rigid endoscopes are used with less risks of general anesthesia, complications and less expensive.[1,2,5,13]

- Food impaction is usually seen in adults and in an abnormally narrowed esophagus,[6,10] such boluses are either removed or pushed to the stomach as Vicari et al did in his study, proved that pushing technique is as safe as retrieval, and no complications reported,[6,10,14]
- In this series if the food bolus is big, a snare was used to remove it in pieces, and the rest pushed down to the stomach, retrieval may be safer than pushing technique because it is not a blind procedure and we have better inspection of the underlying pathology; [9,11,13] Among food boluses, meat is the most common, has no risk of perforation as compared to bones.[1-6,9-12,14]

- Most of our patients (31/35) 89%, with food impaction, had esophageal stricture, the cause of stricture was ingestion of corrosives in (15 patients, 48%), as found in eleven children, and 4 adults (such patients may present several times with food impaction if not dilated well.[6,10]
- GERD strictures in 10 patients (32%) and Schatzki's ring in 6 patients (20%) are more common in other areas, in contrary to corrosive strictures, are seen in elderly patients, in such group good endoscopic examination and biopsy of the esophagus is recommended to exclude malignancy, which is rare, no one has tumor in this series like other studies.[1,10]

- In patients who ingested a piece of bone one should be more cautious in manipulation especially in upper esophagus, embedded bones had higher risk of complication like perforation, which should be diagnosed immediately and referred to surgery for open removal of piece of bone and repair of esophageal tear[15-17].

- Most cases of foreign bodies causing perforation, or injury is due to bone or button batteries impaction in the cervical esophagus, and those patients who need to be referred for surgery as the diagnosis of perforation is made, or if the piece of bone is embedded in the upper esophagus, from the early beginning need operative intervention if retrieval failed.[15,18]
- Weinstock reported no cases of perforation or complication in his series in spite of push technique and use of dilators.[14] and Velitchkov reported 4.8% of his patients required surgery due to perforation from sharp objects.[19]

- Out of our 7 patients with pieces of bone, only 2 (29%) has perforation and needed surgery, this similar to what was reported by Vizcarrondo, a bout (35%).[13]
- Lin has 9.5% of his patients had complications (perforation and neck abscess among 42 patient).[15]
- Other sharp object that passed to the stomach (like pins and needles) need not to be retrieved, especially if are mixed with food in a full stomach, follow up by x-ray films till they came out with defecation this is occurred in 3 patients.

Webb failed to retrieve 2 pins because they were buried in a full fundus [2], only razors blade should be removed because they may cause bleeding and perforation[1,2]

- Three pieces of razor blade was retrieved with an over tube, Webb retrieved such blades and prefer not to be left in the stomach.[1,2] The ingestion of sharp objects like razor blades seen in prisoners and psychiatric patients, usually in normal esophagus i.e., no stricture. [2,9,10,20]
- Dental bridge work if impacted should be removed or pushed to the stomach, in this study one of those pushed to the stomach got impacted in the rectum, that necessitated manual disimpaction.

Ingestion coins and coins like occurs most commonly in children,[1-5,9,11,18] other foreign bodies like batteries, rings, toys, and other funny objects had been reported in literature, most of these were removed by flexible endoscopy.[1-5,18-21]

Mean age 5.2 years, toddlers,[21] most coins can be retrieved while they are in the esophagus, depending on there diameter, it ranges from (1.75-2.5 cm), which is relatively large for this age group, most of coins and coins like can be easily retrieved with a snare,[1-4,13,15,] no complications reported, and those pushed to the stomach, preferred to be extracted, because of reported cases of zinc toxicity.[22]

- Bezoars are real problem if large and adherent or extending to duodenum, phytobezoars if not giant can be removed endoscopically by using different methods, like giant snare or gall stone lithotripter [23-25] In this study 3 patients had phytobezoars which were successfully removed from stomach. One patient with trichobezoars, large, fixed and mixed with chewing gum, was difficult to deal with after 3 long gastroscopy sessions, successfully softened and removed in pieces while the rest came out with stool after using concentrated nitric acid, injected with caution, in the bezoars by sclerotherapy injector, this the first time to use such a strong acid in bezoars in the literature. If this was not done surgery could be the only solution.[26,27]

Conclusion

- Foreign body and food boluses impacted in esophagus, are urgent problem, which need to be managed carefully, flexible endoscopy is considered the treatment of choice, with high success rate more than 93%.
- Failure is due to impacted sharp pieces of bones embedded in upper esophagus, surgery is considered after failure and if the esophagus perforated during endoscopic manipulation.

- Pushing is as safe as retrieval in soft and blunt objects impaction.
- Impacted coins and coins like occur in pediatric age group, with normal esophagus, while food boluses occur in narrowed esophagus.

Acknowledgment: I would to thank Dr M. A.Fahd for his computer support, and both secretaries Manal and Salam for data collection.

References

- 1-Webb WA. Management of foreign bodies of upper gastrointestinal tract: update. Gastrointest Endosc 1995;41: 35-51
- 2- Webb WA, Management of foreign bodies of the upper gastrointestinal tract. Gastroenterology 1988; 94:204-16
- 3-Ratcliff KM,. Esophageal foreign bodies. Am Fam Physician. 1991; 44: 824-31
- 4-Arana A, Hauser B, Hachimi-Idrissi, Vanduplas Y. Management of ingested foreign bodies in childhood and review of the literature. Eur J Pediatr. 2001Aug 160(8) 468-72
- 5-ASGE. Guideline for management of ingested foreign bodies. Gastrointest Endosc 2002;55: 802-6
- 6-Vicari JJ, Johnson JF, Frakes JT. Outcome of acuteesophageal food impaction: success of push technique. Gastrointest Endosc. 2001; 53:178-81
- 7-Campbell JB, Quattrmani FL, Foley LC. Foley catheter removal of blunt esophageal foreign bodies, Experience of 100 consecutive children. Pediatr Radiol 1983; 13: 116-9
- 8-Ginaldi S. Removal of esophageal foreign bodies using a Foley catheter in adults. Am J Emerg Med 1985; 3 64-6
- 9-Berggreen PJ et al, Techniques and complications of esophageal foreign body extraction in children and adults. Gastrointest Endosc 1993;39:626-30
- 10- Longstreth GF, Longstreth KJ, Yoa JF. Esophageal food impaction: epidemiology and therapy. A retrospective, observational study. Gastrointest Endosc 2001;53: 193-8
- 11- Ginsberg GG. Management of ingested foreign objects and food bolus impactions. Gastrointest Endosc 1995;41:33-8
- 12-Mosca S, et al. Endoscopic management of foreign bodies in the upper gastrointestinal tract: report on a series of 414 adult patients. Endoscopy; 2001, 33: 692-6
- 13-Vizcarrondo FJ, Brady PG, Nord HJ. Foreign bodies of the upper gastrointestinal tract. Gastrointest Endosc 1983;29:208-10.
- 14-Weinstock LB, Shatz BA, Thyseen SE, Esophageal food bolus obstruction: evaluation of exraction and modified push technique in 75 cases. Endoscopy. 1999;31(6):421-5
- 15- Lin MT, Yeung CY, Lee HC, Sheu JC, Wang NL, Lee KS. Management of foreign body ingestion in children: experience with 42 cases. Act Pediatr Taiwan. 2003; 44: 269-73
- 16 -Kim JK, Kim SS, Kim JI, Kim SW, Yang YS, Cho SH, et al. Management of foreign bodies in the gastrointestinal tract: an analysis of 104 cases in children. Endoscopy 1999;31:302-4.
- 17-Henderson CT, Engel J, Schlesinger P. Foreign body ingestion: review and suggested guidelines for management. Endoscopy.1987; 19(2) 68-71
- 18- Litovitz Tl, Schmitz BF. Ingestion of cylindrical and button batteries: analysis of 2892 cases. Pediatrics1992; 89: 747-57
- 19-Velitchkov NG, Grigorov GI, Losanoff JE, Kjossev KT. Ingested foreign bodies of the gastrointestinal tract: retrospective analysis of 542 cases. World J Surg 1996;20:1001-5.
- 20- Cheng W, Tam PK. Foreign-body ingestion in children in children: experience with 1265 cases. J Pediatr Surg 1999;34:1472-6.
- 21-Chu KM, Choi HK, Tuen HH, Law SYK, Branicki FJ, Wong J. A prospective randomized trial comparing the use of the flexible gastroscope versus the bronchoscope in the management of foreign body ingestion. Gastrointest Endosc 1998; 47:23-7.
- 22-Bennet DR, Baird CJ, Chan KM, Crookes PF, Bremner CG, Gottlieb MM, et al. Zinc toxicity following massive coin ingestion. Am J Forensic Med Pathol 1997;18:148-53.
- 23-Tohado H, Haruma K, Kitadai Y, Yoshihara M, Shimamoto T, Sumii K, Kajiyama G.Gastric emptying and bezoars in Japanese. Report of five cases. Dig Dis Sci.1993;38:1422-5
- 24-Manbeck NA, Walter MH, Chen YK.Gastric bezoars formation in a patient with scleroderma: endoscopic Removal Using Gallstone Mechanical lithotripter. Am J Gastroenterology, 1996; 91(6)1285.
- 25-Jaume Gaya. et al. Persimmon bezoars: a successful combined therapy. Gastrointest Endosc. 2002; 55:581-3
- 26- Phillips MR, Zaheer S, Drugas GT. Gastric trichobezoars: case report and literature review. Mayo Clin Proc; 1998; 72(7):653-6
- 27-Baskonus I, Gokalp A, Maralcan G, Sanal I. Giant gastric trichobezoars. Int J Clin Pract. 2002; 56(5):399-400.