OUTBREAK OF LARYNGOTRACHEITIS (LT) IN VACCINATED COMMERCIAL LAYER FLOCKS IN PALESTINE

Salameh Barhoom
Clinical Studies , Faculty Of Veterinary Medicine, An- Najah National University

ABSTRACT

This study was conducted during an outbreak of *infectious laryngotracheitis (ILT)* in three flocks hyline breed of commercial layers with a total number of 20.000 housed in cage systems in Bal'a , East of Tulkarem . North Palestine .these flocks were previously vaccinated once at 15 weeks age with attenuated vaccine against ILT disease via cloacae . The clinical findings of the disease were : Respirator)' distress including gasping , coughing , gargling , marked dyspnea and expectorating of vigorously blood stained mucous and some layers showed existence of dried blood around the nostrils and lower beaks , unilateral or bilateral closed eyes , lacrimation and the egg production decreased 30% . The morbidity rate was high and the mortality rate reached 12% . The necropsy findings of dead birds showed mucoid tracheitis , laryngitis , sever hemorrhages in the trachea and the lumens were filled with mucus mixed with blood obstructing the *trachea or larynx* , exudates , caseous material and existence of blood casts along the entire length of the *larynx and trachea* . The disease was diagnosed by isolation of the ILT virus from the dead and sick birds tracheal suspension by culturing onto the chorioallantoic membrane *(CAM)* of 10-12 day- old embryonated chicken eggs and identified by neutralization test using reference anti-ILT serum and quantitative detection of antibodies level in layers sera using ELT-LT EL1SA KIT - *Jordan -Bioindustris Center (JOVAC)* . Histopathological study revealed characteristic intranuclear inclusion bodies in both experimentally infected cocks and tracheal section of sick layers .

Keywords: *linfectious Laryngotracheitis (ILT) , Chorioallantoic membrane (CAM), Enzyme-Linked Immunosorbent Assay (ELISA) , Histopathology.*

INTRODUCTION

Laryngotrachieitis is a viral respiratory tract infection of chickens that may result in sever economic losses due to mortality and / or decrease egg production (Gug & Garcia , 2008). Clinically , the disease may appear in three forms , namely peracute , subacute , and chronic or mild. In the preacute form , onset of disease is sudden with a rapid spread . the morbidity is high and mortality may exceed 50% . Some birds may die in good body condition before the appearance of signs which are characteristic and comprise in difficulty breathing with extension of the neck and gasping in an attempt to inhale . There is gargling , rattling and coughing when birds try to expel the obstructions of the trachea . Clots of blood may be coughed up and can be found on the floor and walls of the house . In the subacute form , The onset of illness is slower and respiratory signs may extend over some days before death are seen . The morbidity is high but the mortality is lower than in peracute form ranged 10% and 30% . Chronic or mild ILT may be seen among survivors of either of the above forms of the disease (Office International des Epizooties , 2004). Laryngotracheitis virus is classified as a member of Genus Iltovirus within the family heipesviridae , subfamily alphaherpesvirnae , 195nm to 250nm in diameter, with a DNA buoyant density of 1.704g/ml .The virus is taxonomically Identified as Gallid herpesvirus 1. AH strains have been demonstrated to be antigenically homogenous (Frederic etal, 1999). Laboratory diagnosis

depends on isolation of the virus , demonstration of the presence of the virus or viral antigens , and detection of specific antibodies in the serum. Histopathological examination of trachea for characteristic intranuclear inclusions may be value(Office International des Epizooties , 2004). The first outbreak of the disease was described in Rhode Island in 1925 , subsequently it has been described in other parts of the world (Biggs ,1982) . This study deals for the first time with an outbreak of laryngotracheitis recently encountered in Palestine where clinical ,virological and pathological studies were conducted .

MATERIAL AND METHODS

An outbreak of *laryngotracheitis* in three layers flocks was investigated . The disease appeared in April 2008 in commercial hyline breed layer flocks with a total number 20.000 housed in cages system in Bal'a Tulkarem Govemorate North Palestine . The layers flock were vaccinated at one day-old chicken (In the hatchery) for *Newcastle disease, Infectious bronchitis , Marek"s disease , Infectious bursal disease* at 11 days-old and boosted at 8 weeks for *Newcastle disease and Fowl pox* at 14 ***U/ceKs*** and *infectious laryngotracheitis* once at 15 weeks .

Clinical examination was preformed on the three flocks , Dead birds and some sick ones were subjected to thorough Post-mortem examination . larynx and parts of tracheal tissues and blood stained tracheal exudates were used for virus isolation and primary tissue section staining for detection of inclusion bodies , parts of tracheal tissues were fixed in 10% neutral buffered formalin and processed for histopathological examination *(Anderson and Gordon , 1999)* .

virus isolation : Tracheal tissues and exudates were collected and processed for isolation of the virus inaccordance *(Jordan , 1964),* 100 I .U penicillin/ml and lOOmg streptomycin/ml were added to the suspension of the specimens and inoculated onto dropped *CAMs* 10-12 day-old embryonated chicken eggs. The inoculated eggs were re- incubated at 37.8c and candled daily , Dead embryos within first 24 hours after inoculation were discarded while other eggs *CAMs* of the dead ones *were* examined for the presence *of pock* lesions until the six days of incubation.

Virus titration : The isolated virus was titrated to determine *EID50 (Reed and Munech , 1938)* , where tenfold dilutions of the pooled harvested allanto-amniotic fluid were inoculated on the dropped *CAM* with 0.1ml of each dilution into five embryonated 10-12 day old.

Identification of the virus : specific *ILT* hyperimmune serum supplied by *(JOVAC Laboratories _ Jordan)* was used in the neutralization test onto dropped *CAMs* of 10-12 day_ old' embryonated chicken eggs, Doubling dilution of serum was added to equal volume of a constant concentration of the virus which equal 100 embryo infective doses *(E1D50)* , the mixture was incubated at 37c for one hour to allow neutralization to occur before inoculation *(Cuningham, 1963)* .

Quantitative detection of specific antibodies against avian ILT virus by ELISA: Blood from sick birds and experimentally infected cocker's were collected, sera were separated and prepared according to manufacturer recommendations of ELT -LTI- ELSA Kit for quantative detection of antibodies against avian *ILT virus (JOVAC, 2007)* . The plates were red using ELISA microplate reader on air ,at 405nm wavelength and the titers were calculated and compared with the reference classification key titers of different level of antibodies .in different groups

Histopath ological identification:

Primary thick smear from the trachea of sick birds and experimentally infected cocker's were used as a rapid technique *(Armstrong, 1959)* for detection of intranuclear inclusion bodies.

Experimental infection:

This experiment was conducted on eight cocks 10 weeks old infected group with the isolated virus *for* re-producing the disease and three cocks were left as a control n&n infected group. The infected group was inoculated intatracheally with 0.1ml containing 10^5 *EID50* of the isolated virus per bird while the control group was inoculated with 0.1ml saline solution per bird . The clinical signs were daily recorded and six cocks were killed after 24 , 28 and 72 hours intervals post inoculation (P.I) and parts of the trachea were fixed in 10% neutral buffer formalin and processed for histopathological examination *(Anderson and Gordon, 1999)* . and viral isolation (Jordan, 1966)

RESULTS

Clinical field signs:

The disease started in a form of outbreak in the flock A suddenly with marked decrease in egg production (30%) and increase in number of dead birds . After that it spread to neighboring flocks (B&C) all the three farms located in the same area with distance two to tliree kilometers . Infected birds often have a bloody beak or blood on the face , head and feather , Respirator}' distress , gasping , coughing , some birds extend their necks and too prolonged difficult inspiration through a wide open beak , gargling and hens shook their heads vigorously in an attempt to dislodge blood stained exudates obstructing the trachea . Some clinical signs were characterized by unilateral or bilateral closed eyes , lacrimation , conjunctivitis and cojunctival edema.. Table No.l Illustrate the mortality rate and percentage of decreased in egg production in the affected flocks with *1LT* during the course of the disease which extended up to two weeks .

Gross and histopathological lesions: Hemorrhages in the trachea , larynx and congestion of the lungs. Lumen of trachea was filled with blood clots, Casts and mucus as seen in Fig. 1.



Fig. I.: Gross pathological tracheal lesions associated with ILT virus showed hemorrhages in the trachea and casts

Histopathological study showed edema on the surface of mucosa , declination of the affected tracheal epithelial cells. Lymphocyte and plasma cells infiltration of mucosa and submucosa, the nucleus of epithelial cell of cocks showed existence of intranuclear bodies at 48 hours post- infection.

Virus ***isolation:*** The virus was isolated from the tracheal suspension collected from the three flocks by culturing onto 10-12 day old chick embryonated eggs after and observed for three to six days after inoculation , The *CAMs* showed generalized edema and development lesions which varied from scattered pocks to large ones with diameter four to five mm .

Virus titration : The titer of isolated ILT virus from the trachea after tow passage on *CAMs* was 10^5 *E1D50* per/ml tracheal suspension .

Neutralization test : The results of this test showed absence of pocks from the reacted isolated virus with hyperimmune serum while untreated virus with hyperimmune serum develop pocks and edema onto CAMs .

ELJSA reading for *antibody levels:*
Level of antibodies against *ILT* virus of both infected flocks and experimental infected cocks are seen in classification of the titer group of manufacturer kit, showed that they are strongly positive with a titer > 24999

primary thick smear stain result :The primary thick smear stain of the lumen tracheal cells of experimental infected cocks and sick birds reveal numeral intranuclear inclusion bodies which is indicator for the disease as seen in fig .2

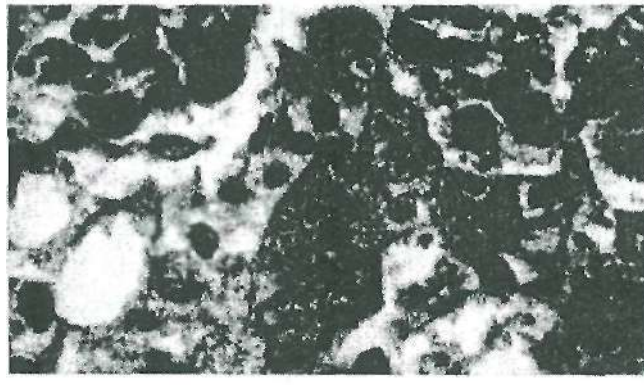

Fig.2: Numerous intranuclear inclusion bodies from the lumen tracheal epithelial cells of experimentally infected cocks .X40.

DISCUSSION

Infectious Laryngotracheitis(ILT) is a respiratory disease of chickens , pheasant and peafowl caused by gallid herpesvirusl , result in sever production losses due to mortality and / or decreased egg production, severe epizootic forms of infection are characterized by signs of respiratory depression , gasping , expectoration of bloody mucus and high mortality (

James & Trevor , 2003) . Mild enzootic form of infection are encountered increasingly in developed poultry industries and manifest variously as mucoid tracheitis , sinusitis , conjunctivitis , general unthriftness and low mortality (Cover and Bentol , 1958) , (Linareset al , 1994) . The disease threat poultry industry because of its contagiousness , rapid spread within a flock to contact other flocks . It was common for passage through a multi age population resulting inappearent enhancement of virulence . The recovered and vaccinated chickens are considered as carriers for ILT virus for months , years and the severity of the disease depends upon the nutritional and hygienic status of the flocks as well as seasonal variations (Matbrough , 1982) .Avian Infectious Laryngotracheals identified as a specific viral disease of chickens in the United States in 1926 , (Frederic et al , 1999) and reported as a problem throughout the world (Biggs , 1982) , in the Middle-East ILT reported in Lebanon (El-Zein A.el-Awar.F.Romona , 1979) and in Saudi Arabia as a cause of serious economical losses in layers and broilers (AL-Zanati and Ahmed , 1995) and in Iraq in layer flocks. This study documents the disease in Palestine in layer flocks in Bal'a East of Tulkarem Governorate . The encountered clinical and postmortem findings are characteristic and similar to those previously reported by others (Barhoom , 1983 , EL - zeinetal 1979, Shihata et al , 1995 and, James and Frevor, 2003) and characterized by respiratory distress , dyspnea , gargling and decrease in the egg production. Sever laryngotracheitis and cast formation along the tracheal lumen. The virus was diagnosed by isolation onto CAMS of 10-12 day- old chick embryo's , detection of intranuclear inclusion bodies from the tracheal epithleal cell's of both infected chickens and experimentally infected cocks , identification using neutralization test with reference anti ILT serum and detection infection level of antibodies titer by ELISA where it showed a titer > 24999 .Some recovered chickens and vaccinated ones become carrier and shed virus for long period of time or much later can shed virus following stress - induced reactivation of latent infection , thus exposing other susceptible birds. In areas where ILT is enzootic , vaccination of layers is frequently practice and is quite effective (Jordan ,1966) In this outbreak ILT virus is suggested to be introduced in the area via carrier birds and spread to neighboring flocks rapidly due to stress of non vaccinated molting.

A recommendation of vaccination for the breeder and layer flocks during rearing periods by twice vaccination is highly and recommended instead of single vaccination , vaccination of molted layer also pr-production period against LT , in addition to practice biosecurity

REFERENCES

AL-hyali.H.M.A. , AL-Khadher ,S. barhoom(2001) . An outbreak of infectious laryngotracheitis in layers in Iraq. Iraq's Journal of Veterinary Science 14:1:37-43.

Al-Zanaty,k and Ahmed,Y.f. 1995.Natural outbreak of infectious laryngotracheitis in broiler chickens in Saudi Arabia . Assiut .Vet.Med.33:66:191-193.

Anderson.G& Gordon K.C.I999. Tissue processing, Microtomy and paraffin section In: BancrofU.D,Stereuse A.Theory and practice of histopathological techniques 4th ed.Edinburgh, Churchill living stone 47-86.

Armstrong,W.H. 1959. A slide smear technique for the diagnosis of *laryngotracheitis* .Avian Dis.3,80-84.

Barhoom. 1983. Infectious laryngotracheitis diagnosis and character of immune response to newly developed inactivated vaccine PhD Thesesis . The Hungarian Academy of science. Budapest - Hungary .

Biggs,P.M.1982.The world of poultry disease. Avian Pathol. 11.281-300.

Cover , MS and W.J. Benton . 1958.The biological variation of infectious laryngotracheitis virus Avian Dis. 2:375-383.

Cuniagham , CH. A laboratory Guide in Virology . 6* ed., Burgess Publ.Com Minneapolis, USA. 1963.

El-Zein A.el-Awar.F.Romona F. 1979.Isolation and identification of an infectious laryngotracheitis virus in Lebanon. Avian Dis. 24:4 . 1062-1065.

Fredric A , MurphyE , Gibbs, P.J., Hozineck , M,Studdert, M.J., .1999.Veterinary Virology, Academic press Newyork.317-318.

Guy ,J.S and Garica.M (2008): *Laryngotracheitis* : In :Disease of poultry , Y.M Sarf , A.M.Fadly ,J.R.Glisson,L.R.McDeugald, L.K.Nolan , D.E.Sweyne.Blackwell publishing. 12th edition. 137-152

Jordan F.T.W.1964. Diagnosis of *Infectious laryngotracheitis* by chick embryo inoculation . J.Comp Pathol .74, 119-128.

Jordan F.T.W.1966. A review of literature on *Infectious laryngotracheitis* . Avian Dis :10 1-26

JOVAC.2007.Jordan Bio- Industries .ELI-LTI ELISA Kit for quantative detection of antibodies against *avian infection larangotracheitis virus* .

Linares , J.A.. Bickford ,A.A ,. Cooper G.L , Charlton B.R. and. Woolck P.R . 1994. An outbreak of infectious laryngotracheitis in California broilers . Avian Dis. 38; 188 - 192 .

Matbrough . J.R . 1982.Epizootology and control of ILT in the USA . Bull of Epizootology . 87 - 94.

Office International des Epizooties .2004 . Manual of diagnostic test and vaccination for terrestrial animals. Last update 1,1 -13.

Reed L.J. and Muench.H.1938. A simple method for estimating fifty percent infective points,Amer.J.Hyg.27,493-497.

Shihata.A.B, Shakal.M, Ali.A, Abd-Elwahd M.1995.Virological and pathological studies on recent isolation of infectious laryngotracheitis virus from Egypt.Vet.Med.J.Gisa3: 359-365.

Table 1 : Mortality rate and percentages of egg production loss in the affected flocks with *ILT* during the course of the disease.

Flock	No.	Type	Age / weeks	Mortality %	Drop in egg production %
A	8000	layer	26	0.20	33
B	8000	Forced molting	60	0.16	30
C	4000	Laver	40	0.1	20